Inflamação Crônica

MPT0206

FMUSP

2009

Aguda × Crônica

- Inflamação aguda: alterações vasculares, edema, infiltrado neutrofílico
- Inflamação crônica: destruição tecidual, infiltrado mononuclear, proliferação de novos vasos e fibrose.

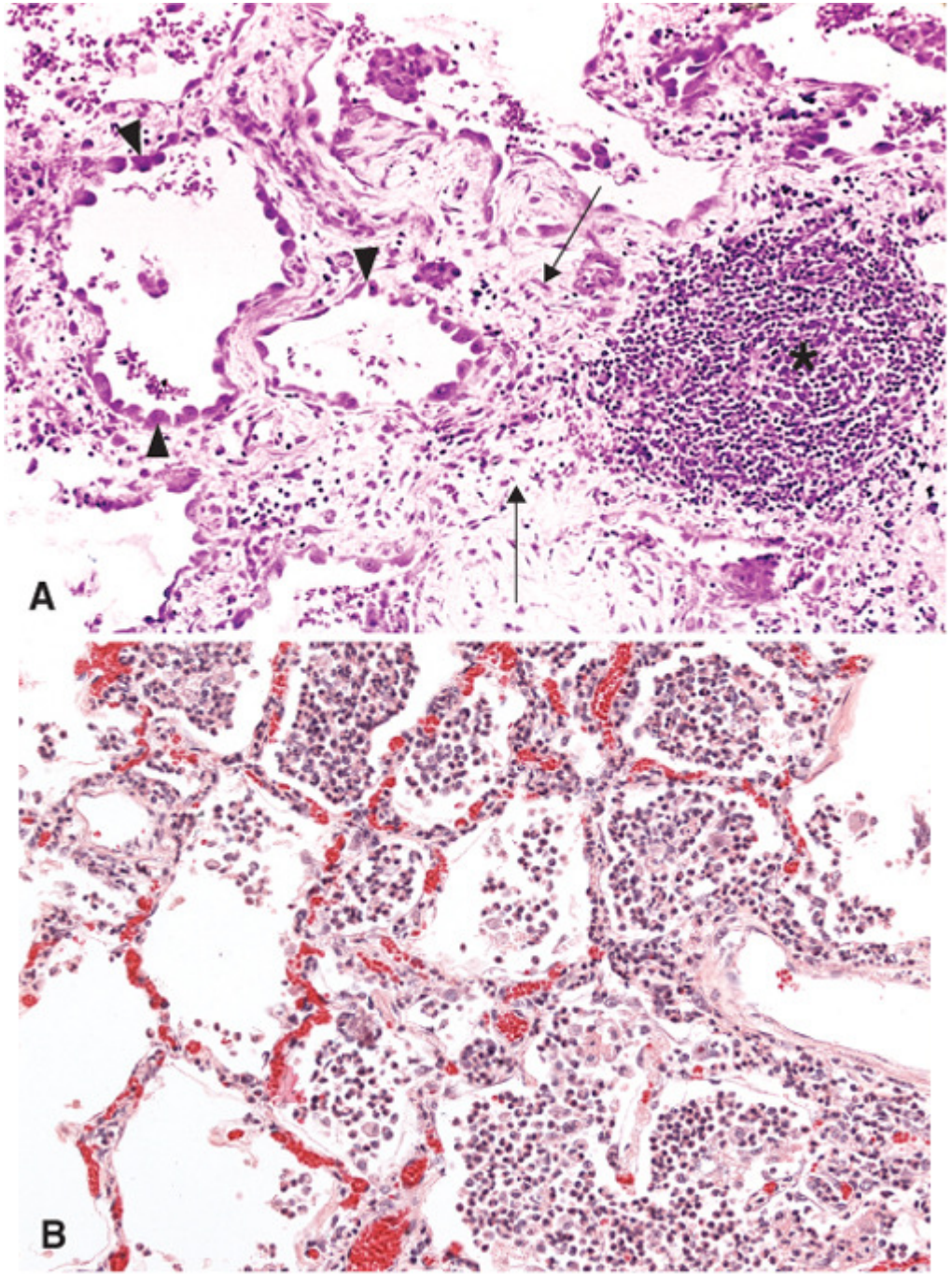

© Elsevier. Kumar et al: Robbins Basic Pathology 8e - www.studentconsult.com

Caso 1

- 35 anos, masculino
- Trabalhador de construção civil
- Sem antecedentes mórbidos
- Tosse produtiva há 2 meses
- Febre vespertina
- Sudorese noturna
- Perda de peso no período

Exames de Imagem

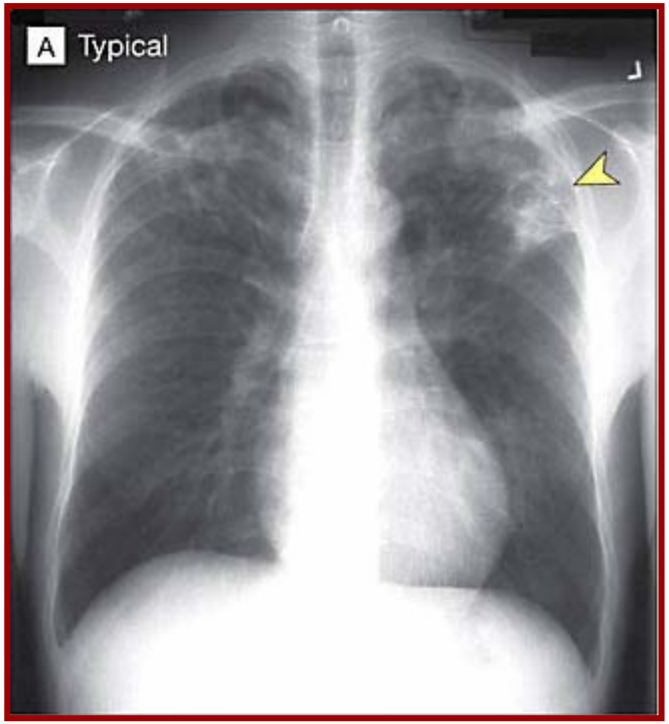

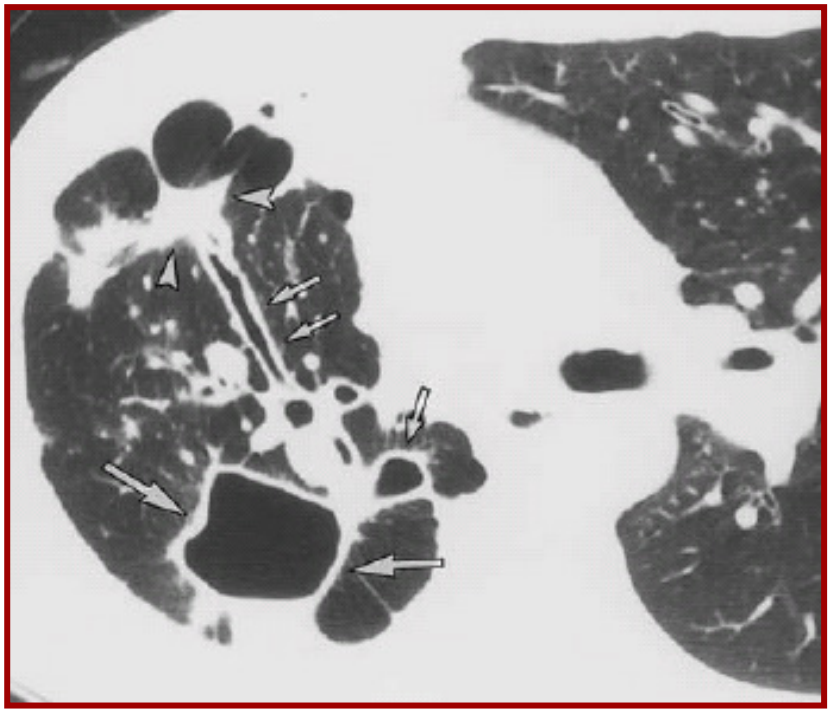

Necrose Caseosa

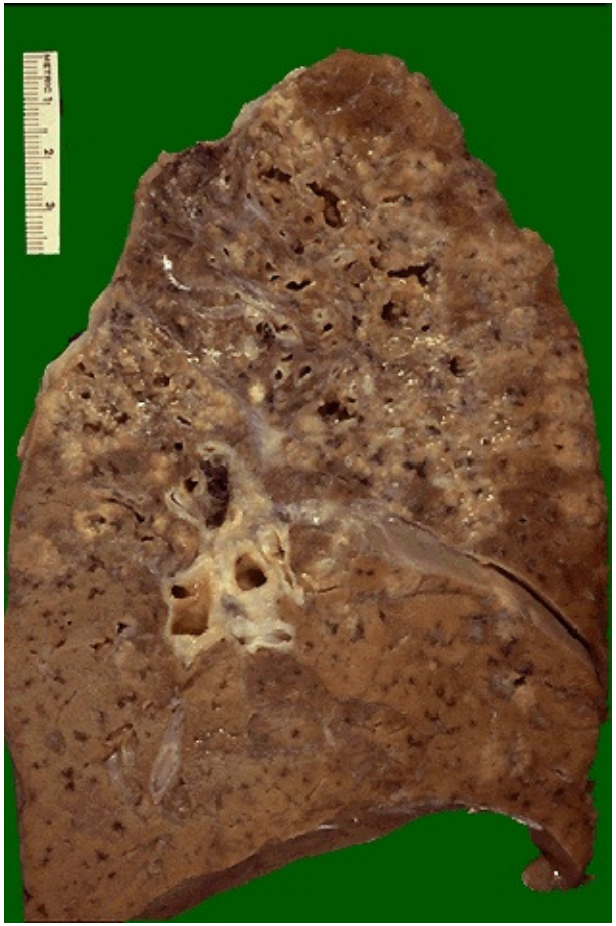

Patologia Granuloma

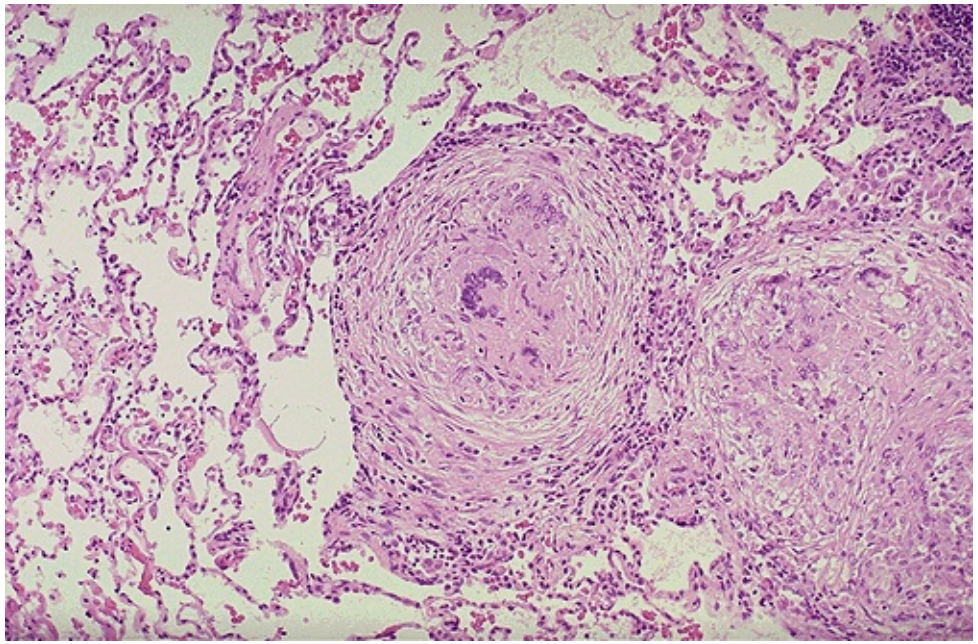

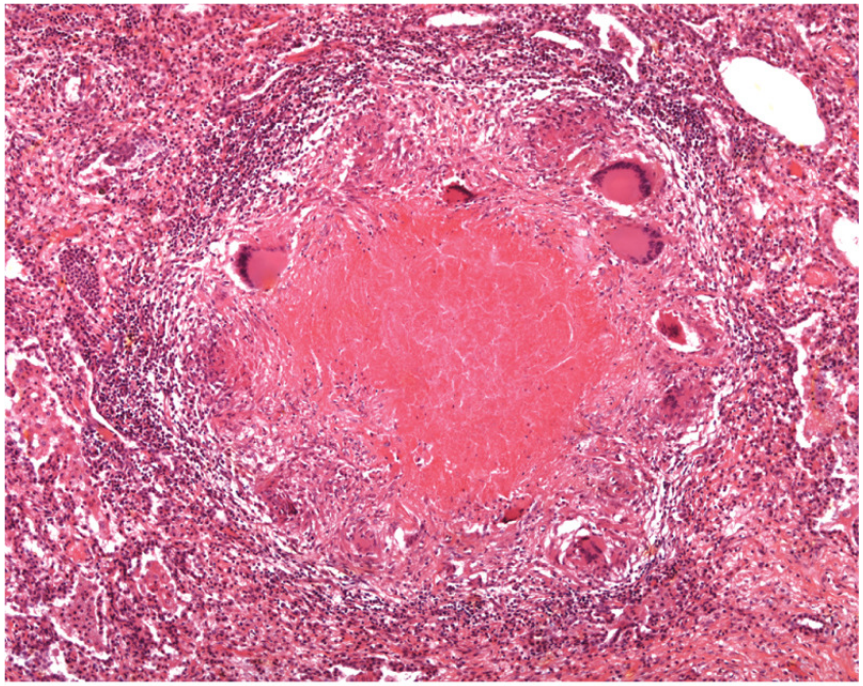

© Elsevier. Kumar et al: Robbins Basic Pathology 8e - www.studentconsult.com

Caso 2

- 55 anos, masculino
- Trabalhou em fábrica de cerâmica
- Cansaço progressivo aos esforços, há anos, com piora recente
- Tosse seca, sem chiado

Imagens

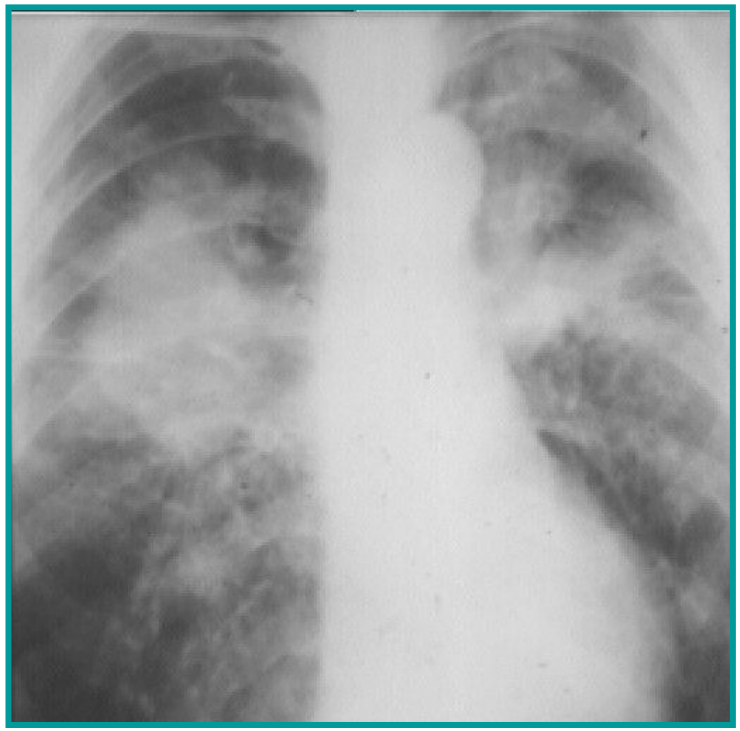

Fig. 8. A 46-year-old man with complicated silicosis. High resolution CT scan at the level of the upper lobes shows bilateral masses of progressive massive fibrosis and multiple nodular opacities.

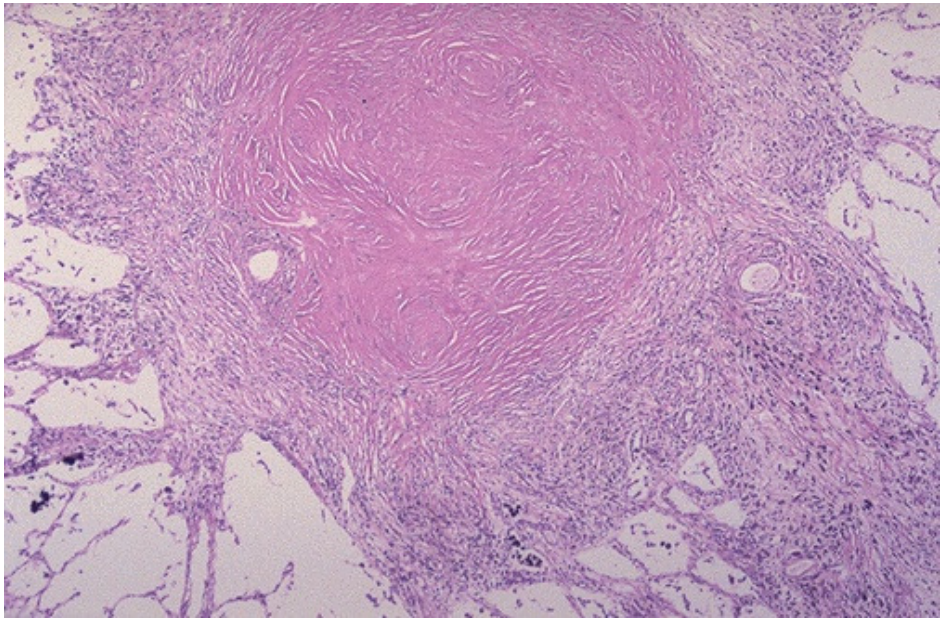

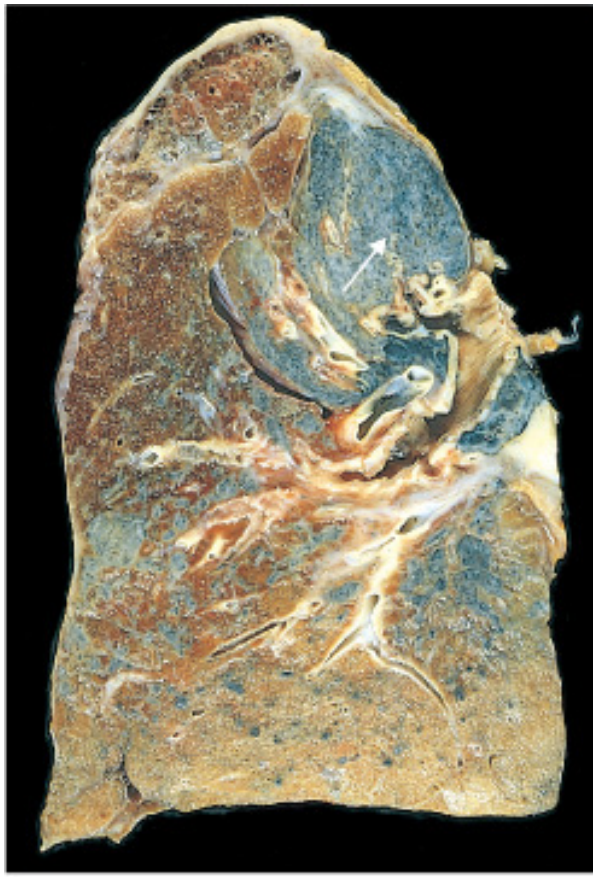

© Elsevier 2005

Caso 3

- 57 anos, sexo feminino
- Artralgia e artrite em punhos, cotovelos, dedos das mãos e tornozelos
- Melhora dos sintomas no decorrer do dia
- Sem sinais de infecção nas articulações ou história de trauma
- Após anos de sintomas, sem tratamento adequado...

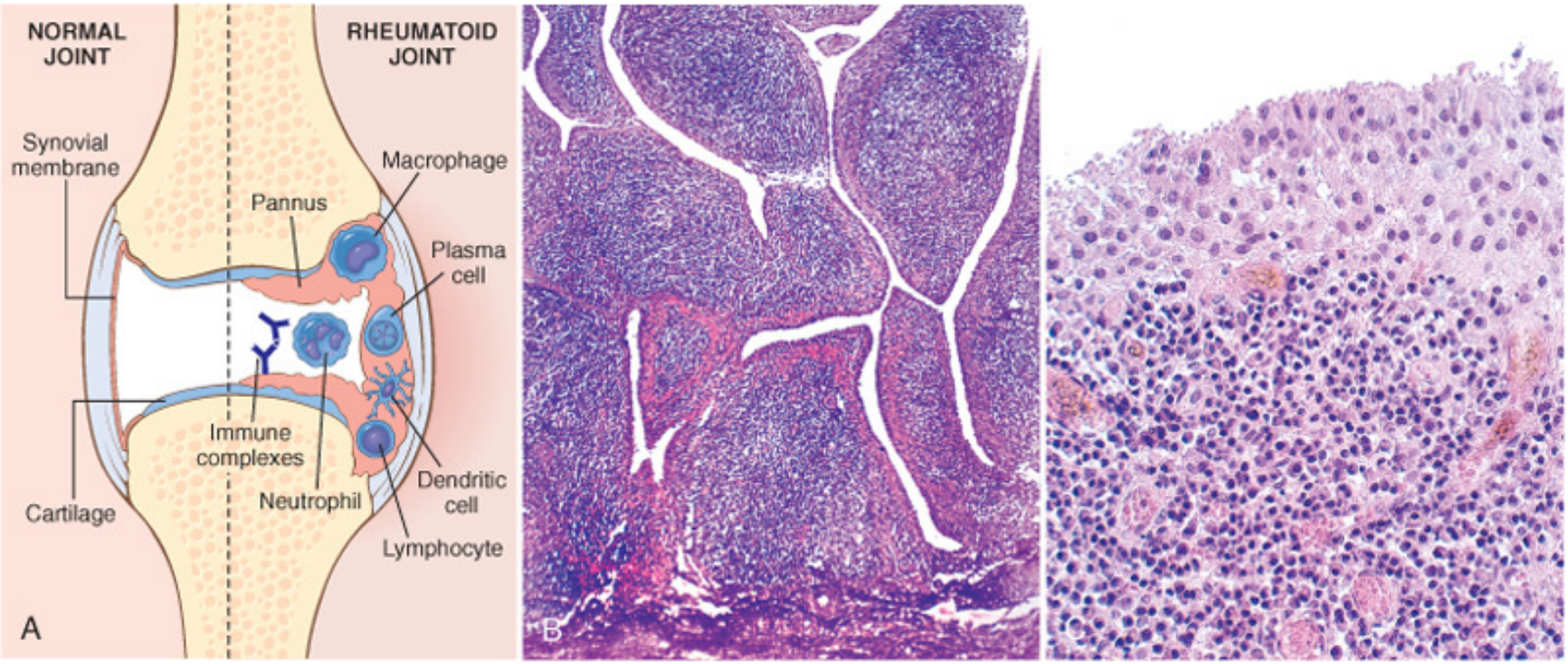

© Elsevier. Kumar et al: Robbins Basic Pathology 8e - www.studentconsult.com

Membrana Sinovial Normal

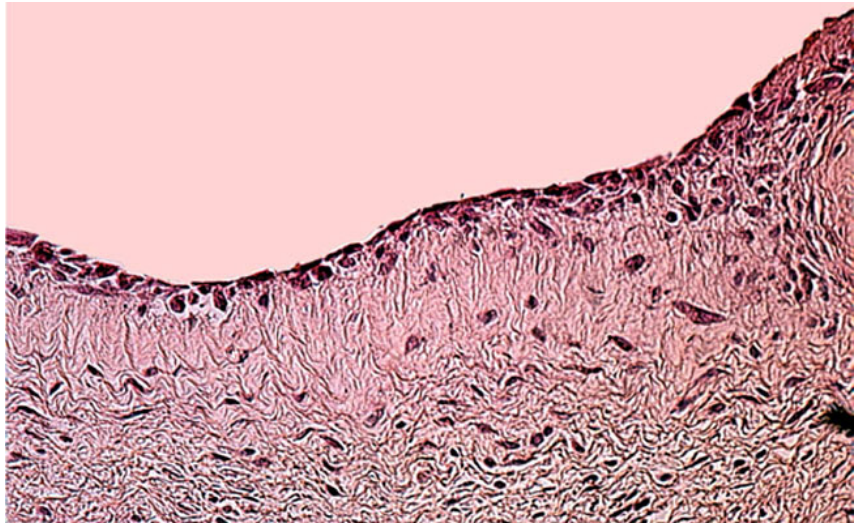

Causas da Inflamação Crônica

- Infecções persistentes:
  - Micobactérias, Treponema pallidum, fungos e vírus
  - Hipersensibilidade tipo IV
- Doenças inflamatórias mediadas por imunidade/doenças autoimunes
- Exposição prolongada a agentes potencialmente tóxicos
  - Material não digerível, tabaco, álcool, lipoproteínas

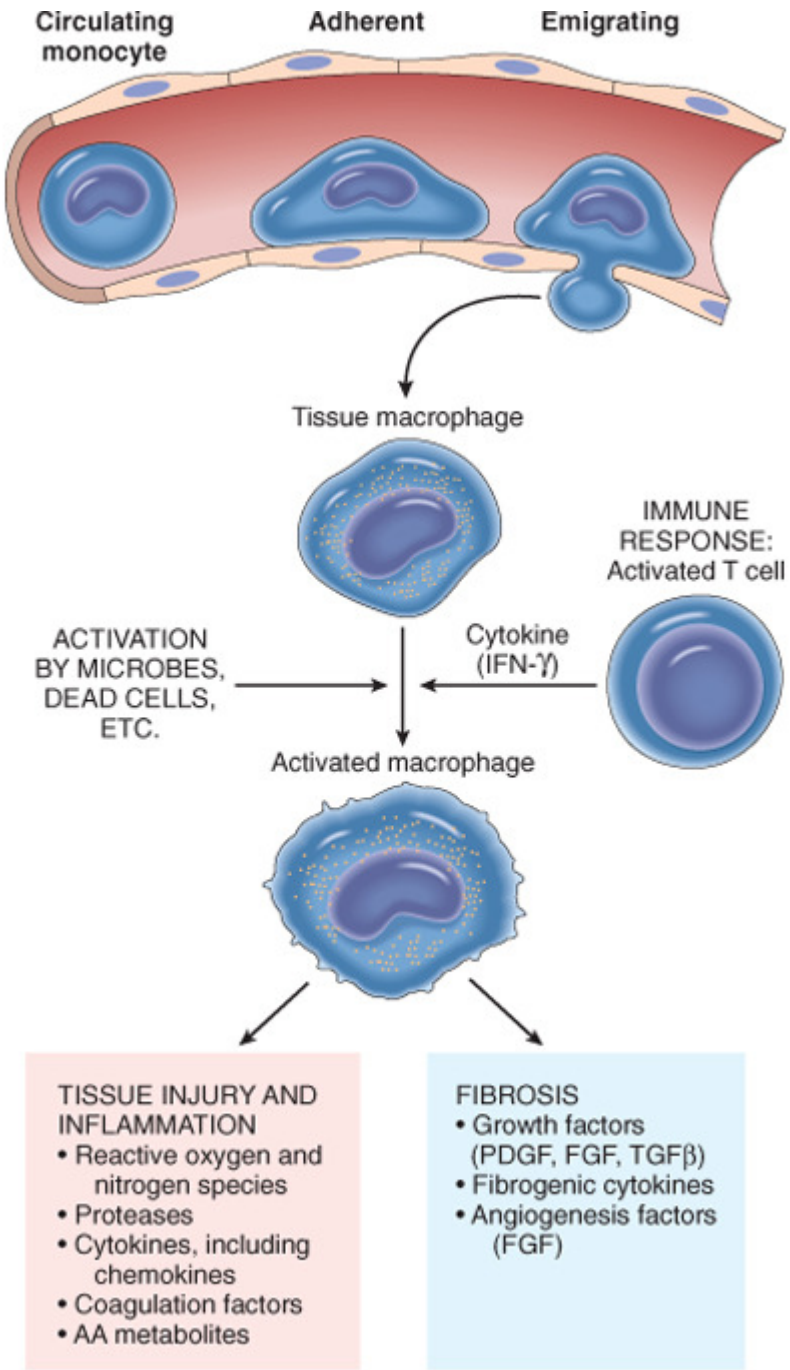

© Elsevier. Kumar et al: Robbins Basic Pathology 8e - www.studentconsult.com

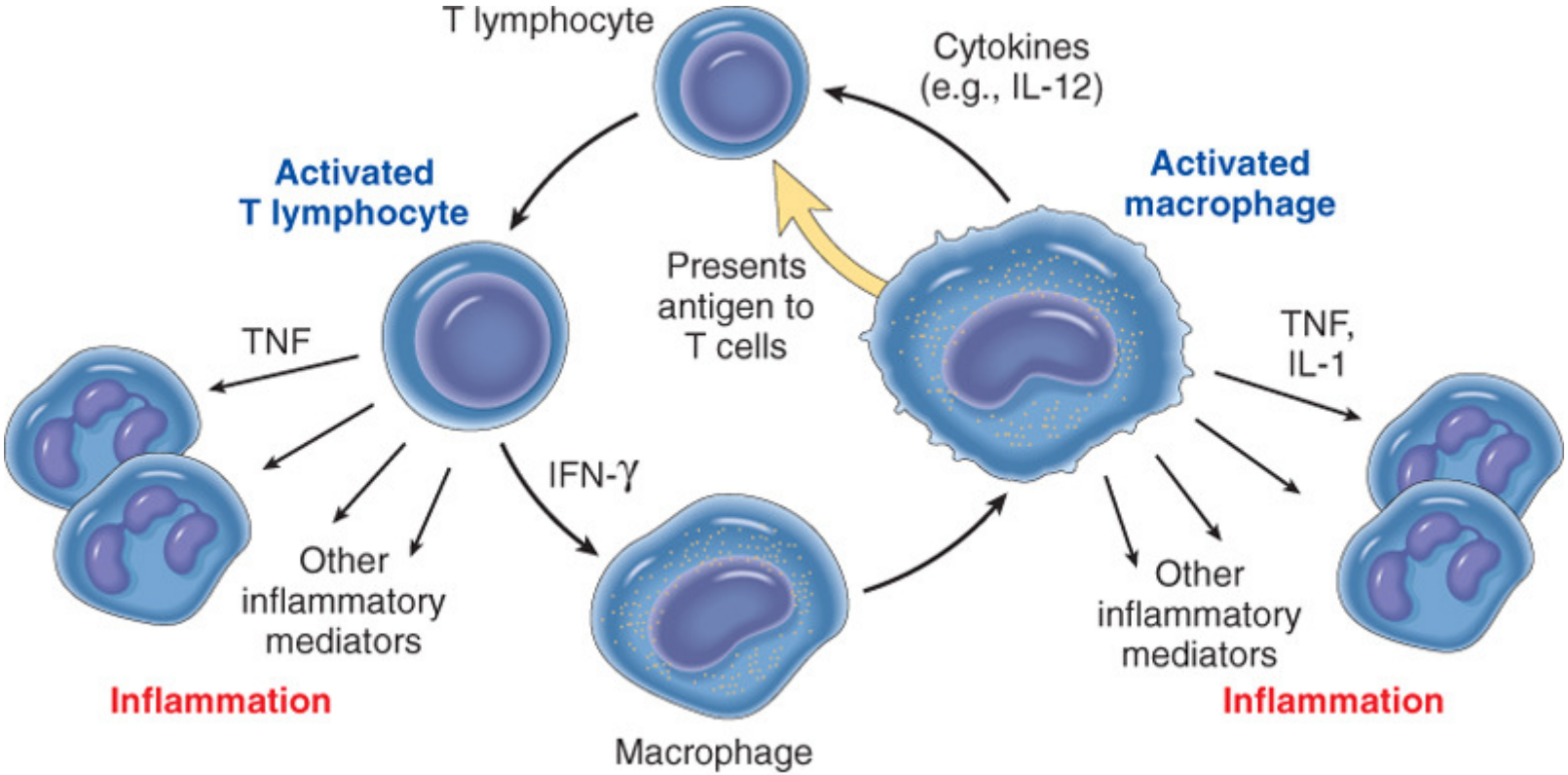

© Elsevier. Kumar et al: Robbins Basic Pathology 8e - www.studentconsult.com

Outras Células de Inflamação Crônica

- Plasmócitos
- Eosinófilos: infecções parasíticas, inflamações mediadas por IgE
- Mastócitos